Back to the Clinic

A Practical Approach to the Veterinary Neurological and Orthopaedic Patient

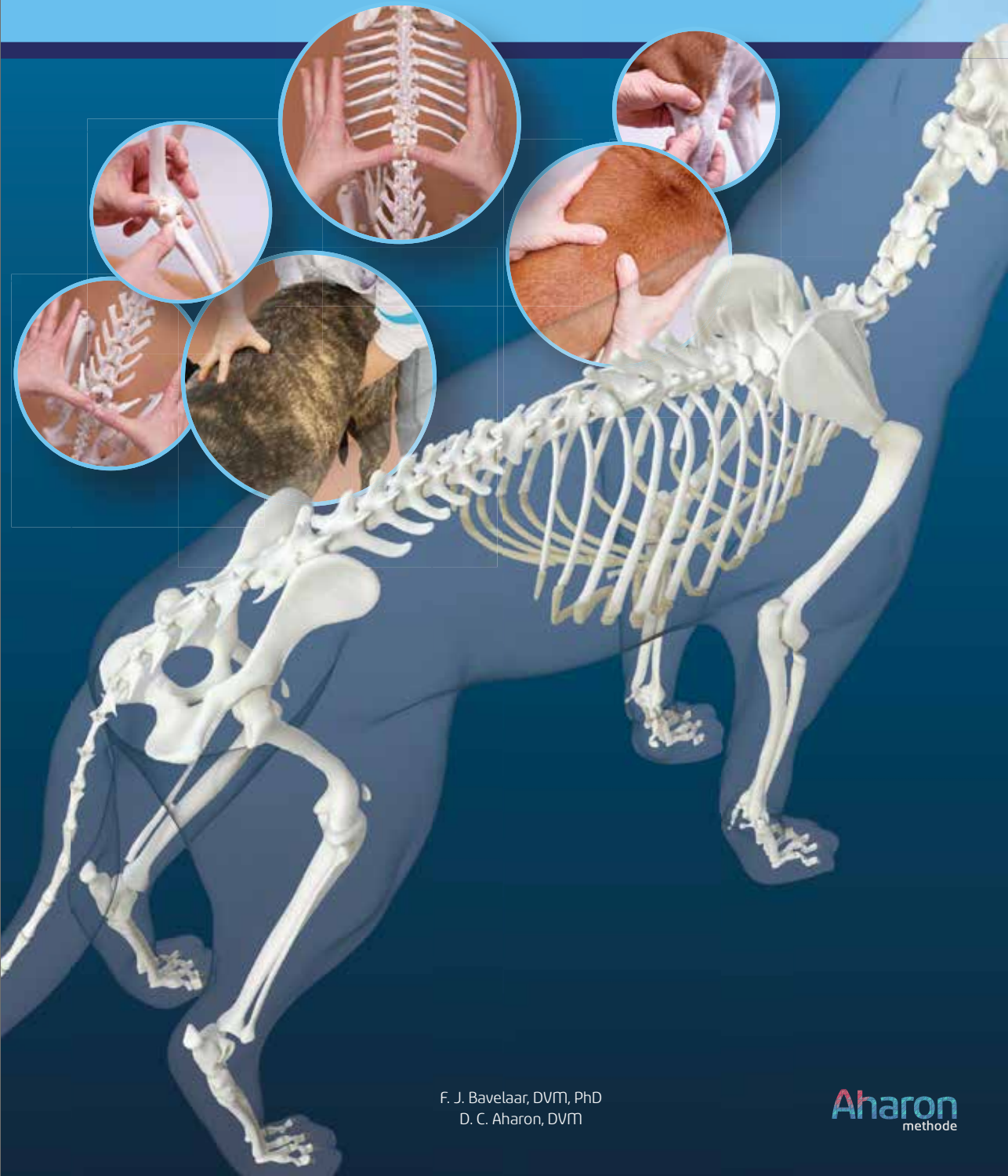

F. J. Bavelaar, DVM, PhD
D. C. Aharon, DVM

Aharon methode

Table of contents

Foreword ... **8**
Preface ... **9**
Introduction ... **10**

Chapter 1
Orthomanual veterinary medicine ... **12**

Chapter 2
Indications and contra-indications for orthomanual veterinary treatment ... **14**

Chapter 3
Misalignments ... **16**

Chapter 4
Performing orthomanual veterinary medicine ... **21**
4.1 Anamnesis ... 21
4.2 Orthomanual examination ... 22
4.3 Treatment ... 24

Chapter 5
Physical examination ... **28**
5.1 Orthopaedic examination ... 28
5.2 Neurological examination ... 31

Chapter 6
Anatomy ... **42**
6.1 The nerves ... 42
- Description of the nerves ... 42
- Neurophysiology of the bladder ... 45
- Nerves involved in defecation ... 47
- Nerves of the forelimbs ... 48
- Nerves of the hind limbs ... 49

6.2 Muscles ... 50
- Muscles of the forehand ... 50
- Muscles of the hindquarters ... 55

Chapter 7
Structure and function ... **59**
7.1 Structure and function of the nervous system ... 59
7.2 Structure of the locomotor system ... 63
7.3 Joints ... 71

Chapter 8
Pain ... **75**

Chapter 9
Movement ... **77**
9.1 Movement patterns ... 77
9.2 Breed-specific movement patterns ... 77

Chapter 10
Orthopaedics ... **84**
10.1 Lameness in the young dog (up to 1 year of age) ... 85
10.2 Non-age-related lameness in the dog ... 102
10.3 Lameness in the cat ... 118
10.4 Muscle conditions ... 123

Chapter 11
Neurology ... **127**
11.1 Symptoms ... 132
- Ataxia ... 132
- Tetraparesis/paralysis ... 137
- Posterior paresis/paralysis ... 139
- Hemiparesis/paralysis ... 139
- Monoparesis/paralysis ... 141

11.2 Disorders ... 143
- Intervertebral disc disease (IVDD) ... 143
- Degenerative lumbosacral stenosis ... 155

11.3 Anatomical localization ... 160
- Central ... 160
  - Inflammatory encephalitis types ... 160
- Cervical ... 161
- Thoracolumbar ... 169
- Lumbar ... 173
- Cauda equina and the lumbosacral junction ... 174
- Peripheral ... 174
  - Neuropathy ... 175
  - Neuromuscular ... 181

Chapter 12
Advanced imaging in spinal pathologies ... **182**
12.1 MRI and CT fundamentals ... 183
12.2 CT of MRI? ... 184
12.3 Disc disease ... 185
12.4 Spinal tumours ... 188
12.5 Caudal cervical spondylomyelopathy or Wobbler syndrome ... 188
12.6 Lumbosacral stenosis/cauda equina syndrome ... 190
12.7 Other ... 192
12.8 Orthomanual therapy ... 193

Chapter 13
Metabolic disorders ... **194**
13.1 Adrenal gland ... 194
- Addison's disease ... 194
- Cushing's disease ... 195

13.2 Thyroid gland ... 196
- Hypothyroidism ... 196

13.3 Diabetes mellitus (DM) ... 198
13.4 Hypokalaemia ... 200
13.5 Pseudomyotonia ... 201

Chapter 14
Medications ... **202**
14.1 Use of corticosteroids for intervertebral disc disease (IVDD) ... 202
14.2 Medications ... 204
14.3 Supplements ... 215

Chapter 15
After care: Mobility, rehabilitation and exercises ... **219**
15.1 Mobility advice ... 219
15.2 Physical therapy ... 226
15.3 Exercises ... 228

Chapter 16
The NVOMD ... **230**

Chapter 17
Training in orthomanual veterinary medicine, Aharon Method ... **232**

Chapter 18
Research and publications ... **234**

Chapter 19
Literature ... **239**

Appendix 1 ... **242**

Appendix 2 ... **248**

Index ... **292**

Abbreviations ... **299**

Chapter 3. Misalignments

Chapter 6 addresses anatomy, and chapter 7 examines structure and function of the nervous system and locomotor system.

The body can be divided in anatomical planes and anatomical directions.

Anatomical Planes

- The dorsal plane: Parallel to the back
- The transverse plane: Perpendicular to the long axis of the body
- Sagittal planes: Divide body sections into right and left sides
- Median: Midline dividing sagittal sections into right and left halves

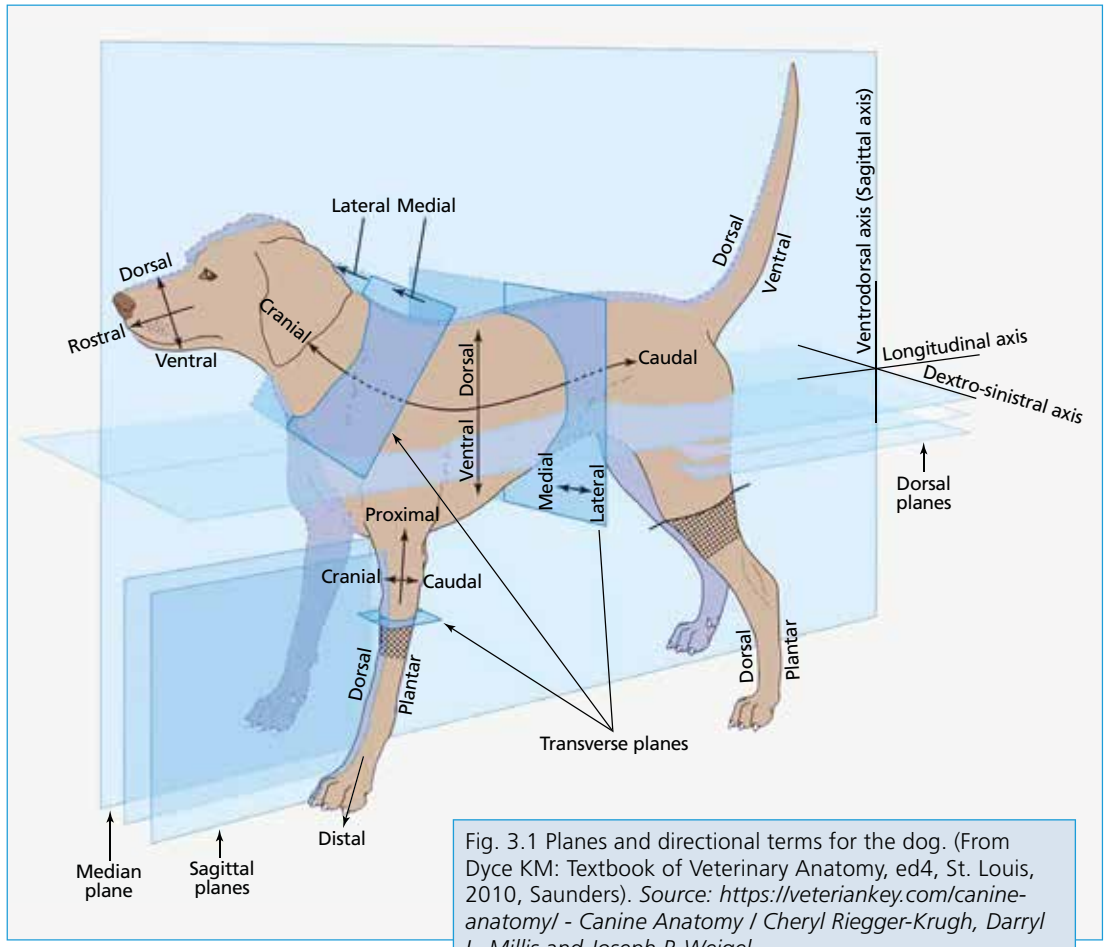

Fig. 3.1 Planes and directional terms for the dog. (From Dyce KM: Textbook of Veterinary Anatomy, ed4, St. Louis, 2010, Saunders). *Source: https://veteriankey.com/canine-anatomy/ - Canine Anatomy / Cheryl Riegger-Krugh, Darryl L. Millis and Joseph P. Weigel*

Anatomical directions

- Dorsal: Toward the spine
- Ventral: Toward the sternum
- Medial: Toward central line
- Lateral: Away from central line
- Cranial: Toward the head
- Caudal: Toward the tail
- Rostral: Toward the nose
- Proximal: Toward the body (trunk)
- Distal: Away from the body

Misalignments are found along one or more of these axes or in a plane. A variety of different misalignments can be found within the vertebrae and in the bone parts of the joints. According to the principles of orthomanual veterinary medicine (Aharon Method), a vertebra is considered misaligned if its positioning deviates from the optimum in relation to the longitudinal, ventrodorsal or dextro-sinistral body axis. In addition, a vertebral position is considered to deviate from the optimum if the articulating surfaces (transverse processes) are not parallel. It is important to keep in mind that misalignments of the vertebrae and bone parts must always be considered three dimensionally, particularly where joints are involved.

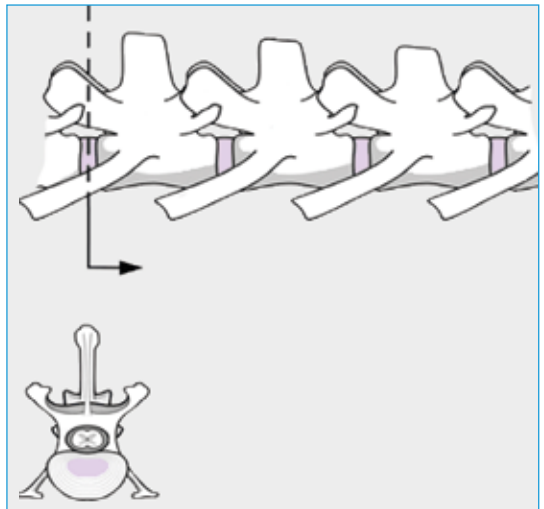

Fig. 3.2 Normal alignment of vertebral column and intervertebral disc. Source: Aharon orthomanual veterinary medicine.

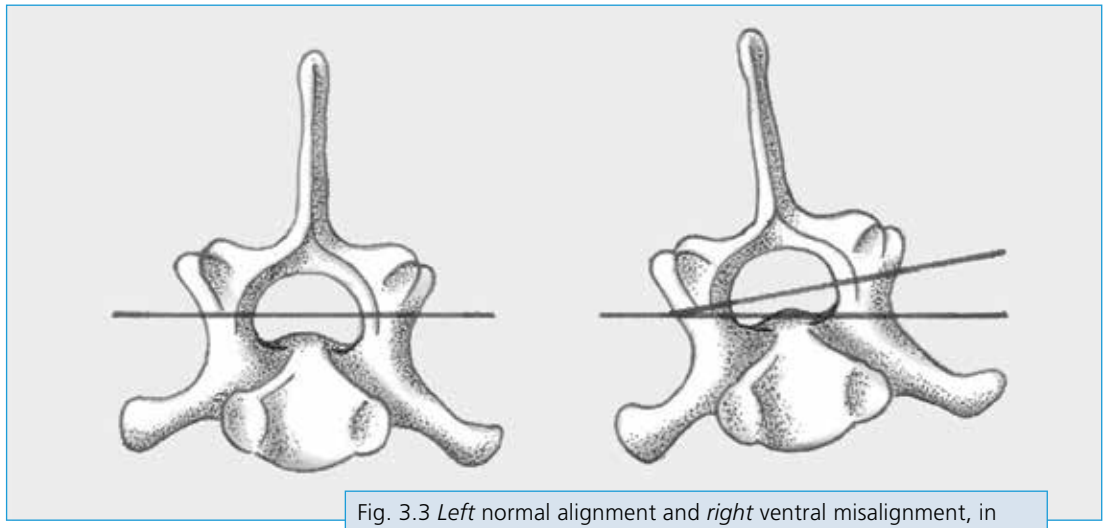

Fig. 3.3 *Left* normal alignment and *right* ventral misalignment, in which the tilting of the vertebral body on the longitudinal axis is clearly evident. *Source: Aharon orthomanual veterinary medicine.*

Strength is determined within the brainstem – spinal cord – nerves
Coordination is determined within the cerebellum – brainstem – spinal cord.
Lesions in the brainstem lead to: vestibular ataxia + cranial nerve deficiency + weakness.
Lesions in the spinal cord lead to ataxia + weakness.

➡ a distinction between a lesion of the brainstem and of the spinal cord can therefore be made by involvement of the cranial nerves.

Lesions in the cerebellum lead to: only ataxia, not weakness.

Posture

To assess posture, the position and carriage of the head, body and legs are evaluated. If the animal seems to be exhibiting a problem in head carriage, take a good look at the alignment of the eyes. Sometimes head carriage can appear off because one ear is drooping, but the eyes are level. "Head tilt" occurs as a result of a lesion to the cerebellum and the vestibular system. "Head turn" occurs due to a lesion to the cerebrum.

Schiff-Sherrington posture: The forelimbs exhibit rigidity, with paresis in the hind limbs. This is due to a lesion of the spinal cord between T3 and L3.

Problems in back posture:

- Kyphosis (roached back): Pain in the thoracic region of the spine.
- Lordosis (hollow back): Is rarely seen, often the consequence of weakness.
- Scoliosis: Occurs as a result of a congenital malformation.

Table 5.1
Lower motor neuron paresis/upper motor neuron paresis differentiation criteria

Criteria	Lower motor neuron paresis	Upper motor neuron paresis
Posture	Difficulty supporting weight. Crouched stance as a result of overflexion of the joints	Often normal (unless the animal is paralysed). Abnormal limb position (knuckling, abducted, adducted or crossed over)
Gait	Short strides. Tendency to collapse	Stiff and ataxic strides. Delayed protraction
Motor function	Flaccid paresis/paralysis	Spastic paresis/paralysis
Segmental reflexes	Decreased to absent	Normal to increased
Resting muscle tone	Decreased resistance	Slight resistance
Passive limb flexion/extension	Decreased resistance	Slight resistance
Muscle atrophy	Early and severe neurologic atrophy	Late and mild disuse atrophy

Source: Platt and Garosi (2012).

Hands on examination

The second component of the examination consists of testing the reflexes. Four reflex groups can be tested:

- Reflexes involving the cranial nerves
- Postural reactions and proprioception
- Spinal reflexes
- Pain sensation

Note: If an animal can walk normally, the reflexes will also be normal.

Elicitation of the reflexes is important to identify the location of a problem.

Table 5.2
Localization of a lesion on the spinal cord. UMN = upper motor neuron; LMN = lower motor neuron.

	C1-C5	C6-T2	T3-L3	L4-S1	S1-S2
Forelimb	UMN	LMN	Normal	Normal	Normal
Hind limb	UMN	UMN	UMN	LMN	

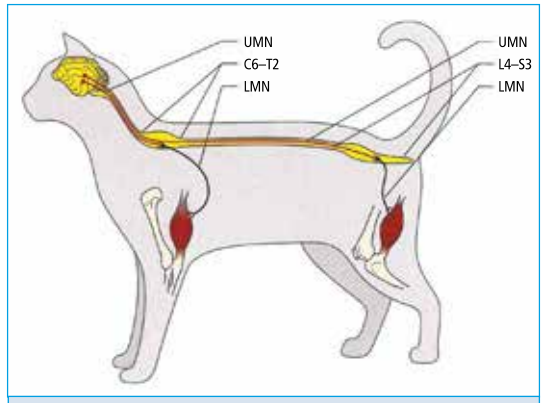

Fig. 5.2 Upper motor neuron (UMN) and lower motor neuron (LMN) systems. *Small Animal Neurological Emergencies. Manson Publishing/The Veterinary Press ISBN 978-1-84076-152-8.*

Reflexes involving the cranial nerves

Most cranial nerves originate in the brainstem. Often a problem in the brainstem affects multiple nerves. Anatomical localization in the brain is always bad news. A lesion of the brainstem causes impairment of the cranial nerves, weakness and ataxia. If there is a lesion external to the brain, there will only be a defect of the cranial nerves. When evaluating the cranial nerves, always listen carefully to what the owner has noticed, and closely observe the animal yourself!

Smell (CN I)

Place a food treat under the animal's nose, and see if the animal sniffs at it.

Eyes

Always start by looking at the eyes. Are there signs of anisocoria, abnormal pupil size or an unusual eye position?

Vision (CN II = optic nerve)

Drop a cotton ball and observe whether the animal follows it with its eyes.

Menace response (CN II and VII)

An animal should see the menace, or threat, and respond by blinking. If the patient does not respond, always test the blink reflex (by touching the animal's head). *This reflex often does not work in cats* (it is influenced by behaviour). Always test both eyes!

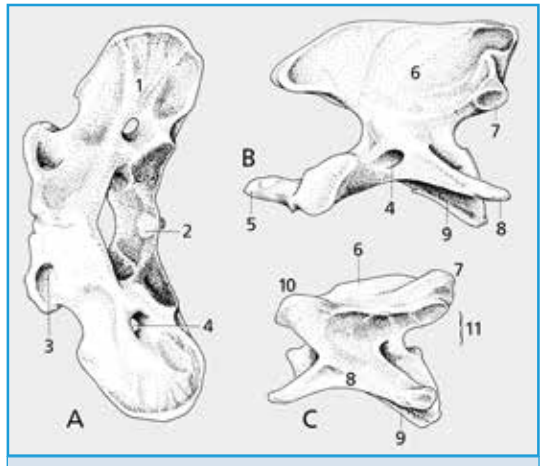

Fig. 7.4 Cervical vertebrae of the dog; cranial is to the left. A. Atlas, dorsal view. B. Axis, lateral view. C. Fifth vertebra, lateral view. 1. Wing of atlas; 2. fovea dentis; 3. lateral vertebral foramen; 4. transverse foramen; 5. dens; 6. spinous process; 7. caudal articular process; 8. transverse process; 9. body; 10. cranial articular process; 11. position of vertebral foramen. *Source: Dyce, Sack and Wensing's Textbook of Veterinary Anatomy.*

The last section of the cervical spine is the most flexible part of the vertebral column. In addition, a fair amount of movement is possible in the caudal thoracic part and in the cranial lumbar part of the spine.

In the pelvis the propulsive force of the hind limbs is transferred via the pelvis and sacrum to the vertebral column.

Fig. 7.5 Nuchal ligament of the dog. 1. Wing of atlas; 2. spinous process of axis; 3. nuchal ligament; 4. spinous process of first thoracic vertebra; 5. plate-shaped extention of transverse process. *Source: Dyce, Sack and Wensing's Textbook of Veterinary Anatomy.*

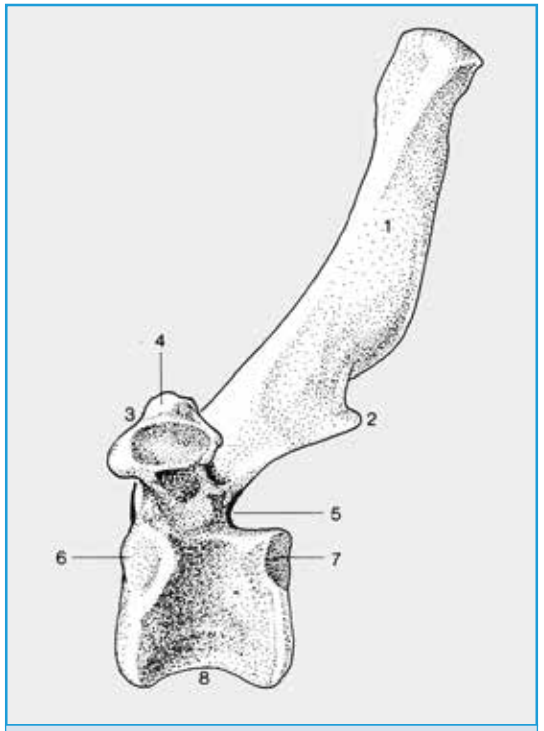

Fig. 7.6 Thoracic vertebra of the dog; left lateral view. 1. Spinous process; 2. caudal articular process; 3. transverse process with costal fovea; 4. mamillary process; 5. caudal vertebral notch; 6, 7. costal foveae; 8. body. *Source: Dyce, Sack and Wensing's Textbook of Veterinary Anatomy.*

Each individual vertebra consists of a vertebral body, a vertebral arch, a spinous process and two transverse processes. The vertebral arch supports the facet joints between the vertebrae. The spinous process is especially well developed in the thoracic region. In addition, each thoracic vertebra corresponds with a pair of ribs. The ribs extend caudally. If you follow a rib upwards, you end up about two vertebrae caudal.

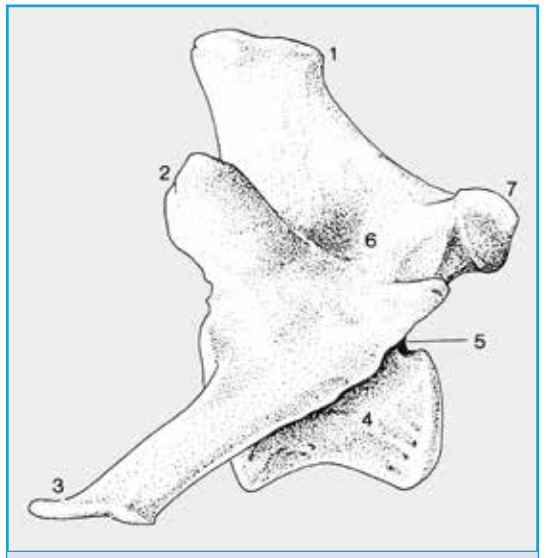

Fig. 7.7 Lumbar vertebra of the dog, left lateral view. 1. Spinous process; 2. cranial articular process; 3. transverse process; 4. body; 5. caudal vertebral notch; 6. arch; 7. caudal articular process. *Source: Dyce, Sack and Wensing's Textbook of Veterinary Anatomy.*

Between the vertebrae are intervertebral discs, with the exceptions of between C1 (atlas) and C2 (axis) and in the sacrum. The intervertebral disc, or discus intervertebralis, consists of a fibrous ring (annulus fibrosus) and a centre with a gelatinous substance (nucleus pulposus). The structure of the intervertebral discs allows for shock absorption and distribution of pressure.

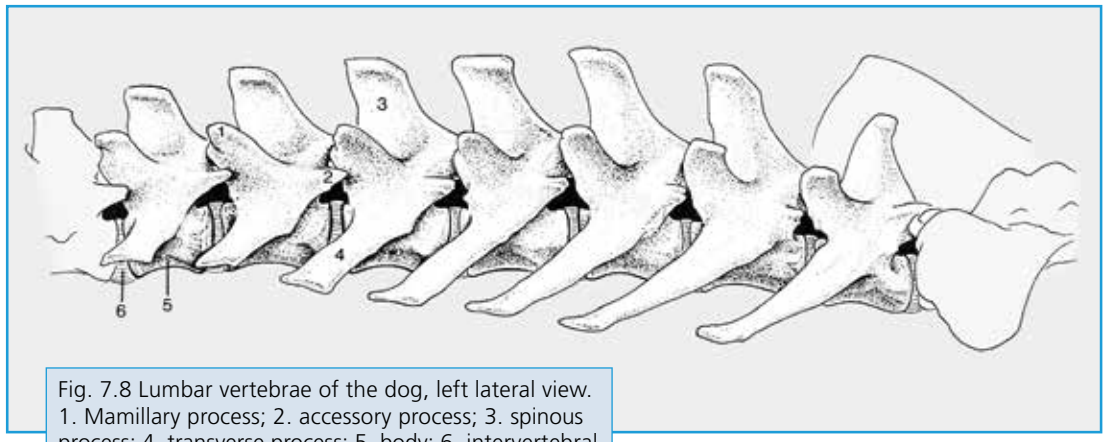

Fig. 7.8 Lumbar vertebrae of the dog, left lateral view. 1. Mamillary process; 2. accessory process; 3. spinous process; 4. transverse process; 5. body; 6. intervertebral disc. *Source: Dyce, Sack and Wensing's Textbook of Veterinary Anatomy.*

The tarsus is a composite joint. Flexion and extension in the joint effectively occur only between the tibia and the talus.

Mobility of the joints

- Toes: Movement on one plane (hinge joint).
- Carpus: Movement on one plane (hinge joint).
- Elbow: Movement on one plane (hinge), as well as supination, 35-160 degrees, and pronation, 60 degrees.
- Shoulder: Movement in multiple directions (ball-and-socket joint).
- Tarsus: Movement on one plane (hinge joint).
- Stifle: Movement on one plane, but some slight lateral and medial movement is possible.
- Hip: Movement in multiple directions (ball-and-socket joint).

Table 7.1
Range of motion of various joints. Data from Reliability of goniometry in Labrador Retrievers. Jaegger G., Marcellin-Little D.J., Levine, D. Am. J. Vet. Res. 2002, 63:979-986.

Joint	Range of motion	
	Flexion	Extension
Shoulder (relative to scapula)	Up to 57°	Up to 165°
Elbow (relative to humerus)	Up to 36°	Up to 166°
Carpus (relative to antebrachium)	Up to 32°	Up to 196°
Hip (relative to the axis of the pelvis)	Up to 50°	Up to 162°
Stifle (relative to femur)	Up to 41°	Up to 162°
Tarsus (relative to the tibia with stifle joint at 90°)	Up to 38°	Up to 165°

Puncture points in joints

It is important to know where the various joints can be punctured. These are also the places where any excess fluid or swelling of the joints can be felt.

Puncture of joints can be performed for diagnostic or therapeutic intraarticular injections (e.g., injection of corticosteroids or autologous plasma or stem cells for arthrosis). Diagnosis of polyarthritis requires puncture of multiple joints. This should always be done under a light anaesthetic, as any movement of the limb and joint during the procedure can release a quick inflow of blood, in which case, interpretation of the joint fluid is no longer possible.

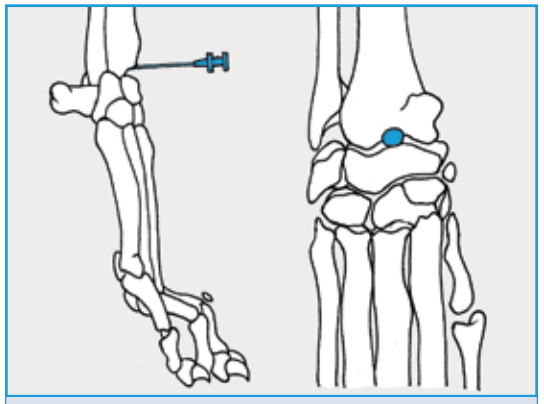

Fig. 7.19 Puncture point in canine carpus. *Source: Small Animal Clinical Techniques, S.M. Taylor, 2010, Saunders Elsevier.*

Carpus

Puncture is done in the antebrachiocarpal (= radiocarpal) joint, with the carpus fully flexed. The joint is palpable as a depression, or indentation. The puncture is done medial to the extensor tendon, or otherwise lateral to the tendon of the M. Extensor carpi radialis.

Tarsus

Puncture is done in the talocrural joint. Use flexion and extension of the tarsus to find the correct position. The joint should be held in neutral position. The tarsus can be punctured in several places: Anterolateral, lateral and caudal.

- Anterolateral: Just under the tibia, just medial to the lateral malleolus fibula (Fig. 7.20).
- Lateral approach: With partial flexion, palpate the malleolus fibula (Fig. 7.21).
- Caudal approach: Use flexion and extension to detect the spot, between the tibia and talus (Fig. 7.22).

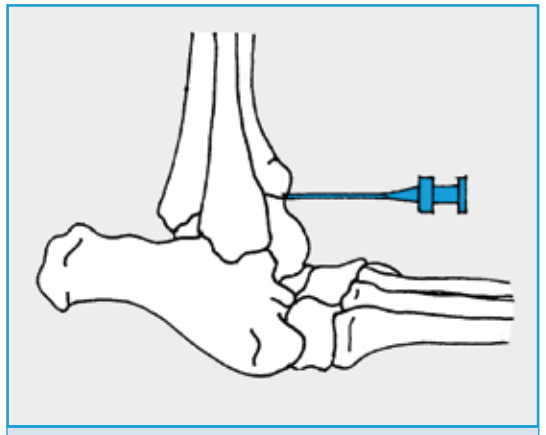

Fig. 7.20 Puncture point in canine tarsus. Anterolateral approach.

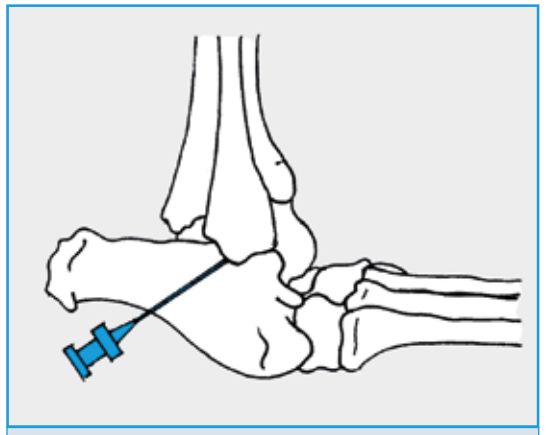

Fig. 7.21 Puncture point in canine tarsus. Lateral approach.

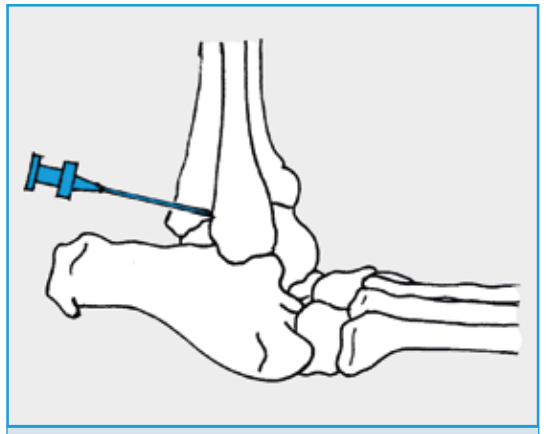

Fig. 7.22 Puncture point in canine tarsus. Caudal approach.

Chapter 12.
Advanced imaging in spinal pathologies

By Ángel María Hernández Guerra
Department of Veterinary Medicine and Surgery, Universidad Cardenal Herrera-CEU, CEU Universities, Tirant lo Blanc 7, 46115 Alfara del Patriarca, Valencia, Spain.
For sources in this article see list of literature (chapter 19).

Despite the great advancements in imaging, clinical and neurological examination remain the cornerstones of diagnosis of spinal problems. No complementary test replaces accurate neurolocalization and thorough clinical examination. Remember, we treat animals, not images. Nonetheless, diagnostic imaging can help us reach a specific diagnosis, localize a lesion and provide a realistic prognosis.

The most important imaging techniques are x-ray, computerized tomography (CT) (or CT myelography) and magnetic resonance imaging (MRI). CT and MRI are both far superior to x-ray. However, the latter is still widely used and recommended for general purposes, due to its ready availability.

Nonetheless, an x-ray can show only very apparent lesions, such as hemivertebrae, bone tumours or discospondylitis. Therefore, we usually need either a CT or an MRI to make a confident diagnosis.

Fig. 12.1 CT scanner



Fig. 12.2 CT scanner with cover removed to show internal components. Legend: T: X-ray tube, D: X-ray detectors, X: X-ray beam, R: Gantry rotation. https://en.wikipedia.org/w/index.php?title=CT_scan&oldid=931133973 (accessed 30 December 2019).

12.1 MRI and CT fundamentals

Both MRI and CT images are computer generated. The computer acquires and processes data to create a picture of a "slice" of the patient.

In a CT scan, the data is acquired by means of an x-ray tube that rotates around the patient. The tube is connected to detectors of the radiation passing through the patient's body. As in conventional radiology, x-rays that pass through the patient are attenuated according to tissue thickness and density. The computer uses the information provided by the detectors to create a black and white image (figure 12.1 and 12.2).

The attenuation coefficient (or radiodensity) of each tissue is represented in grey tone scale. This attenuation coefficient of radiation within the different tissues is expressed in Hounsfield units (HU). Thus, water has a value of 0 HU, the cortical bone of +3000 HU and air -1000 HU.

MRI, in contrast, generates images using magnetic fields and radio waves. A strong magnetic field causes all the protons in a patient's body to spin parallel to the field direction. If the magnetic field is disrupted, the nuclei recover their normal spin direction, producing radio signals which decrease over time as the result of two processes, known as T1 and T2 relaxation. These parameters differ depending on tissue composition. Soft tissue produces a wide range of radio signals, while bone generates very little differentiation. Computers use this variety of emitted signals to build an image, exploiting these differences to differentiate tissue.

There are two basic types of MRI: low-field and high-field. The difference relates to the magnet. Low-field MRI machines are usually open design and range from 0.2 to 0.6 Teslas (T) whereas high-field scanners are at least 1.5 T. Low-field MRI equipment is far more affordable, and positioning patients is easier. High-field MRI yields images of much greater quality, with thinner slice acquisition and faster scan times, thanks to the signal to noise ratio.

Hansen Type II

- In this type of disc disease, the herniated material is seldom clacified so CT scan will not usually show changes.
- With a 3D CT scan, misalignments (for example, in the lower back) may be very visible.
- CT myelography can provide extremely good information about the area and type of compression, perhaps as good or better than information from MRI (figures 12.7 to 12.11).
- According to orthomanual principles, chronic IVDD is usually associated with vertebral misalignments. On these, CT could potentially provide optimum information.

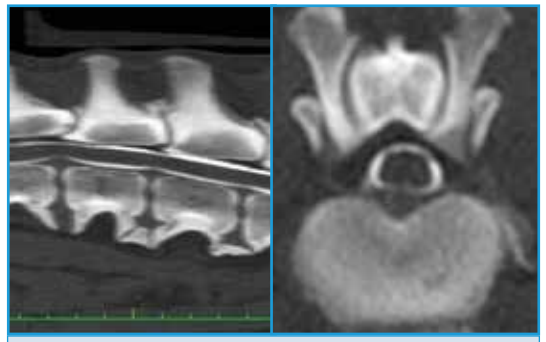

Fig. 12.8 Hansen type II - Disc disease myelogram.

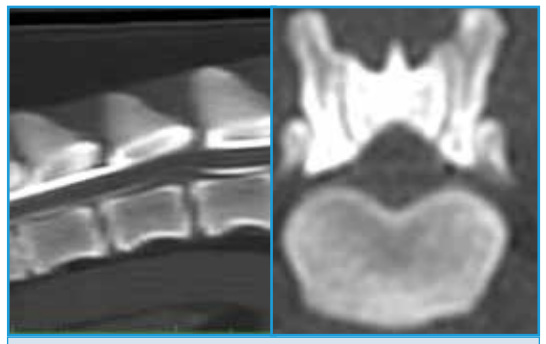

Fig. 12.9 Hansen type II - T13-L1.

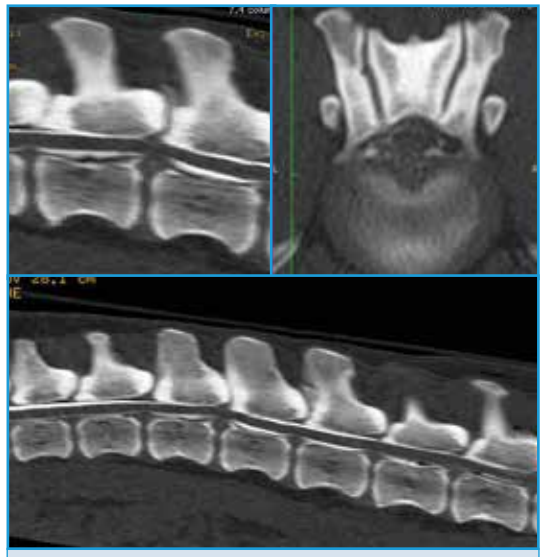

Fig. 12.7 Hansen type II - Disc disease myelogram.

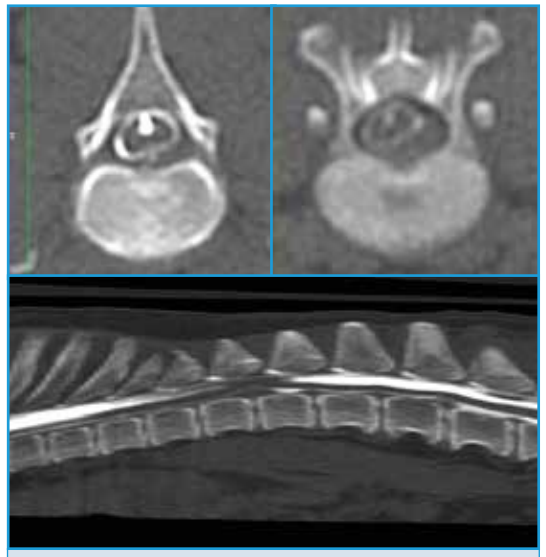

Fig. 12.10 Hansen type II - With syringomyelia.

Acute non-compressive disc disease, or high-velocity low-volume IVDD. Also commonly, though erroneously, called Hansen type III

- This disease is neither compressive nor does it involve calcified disc material. Therefore, MRI is the superior imaging technique, as it shows intramedullary changes and the involved discs.
- Nevertheless, the changes that can be seen using CT myelography will usually be enough to rule out compressive disorders; although with a CT scan, acute non-compressive disc disease would be impossible to differentiate from from ischemic disease (i.e., a fibrocartilaginous embolism). Treatment is similar in both cases (physical rehabilitation). The prognosis would, in both cases, greatly depend on clinical findings rather than imaging (figures 12.12 to 12.15).

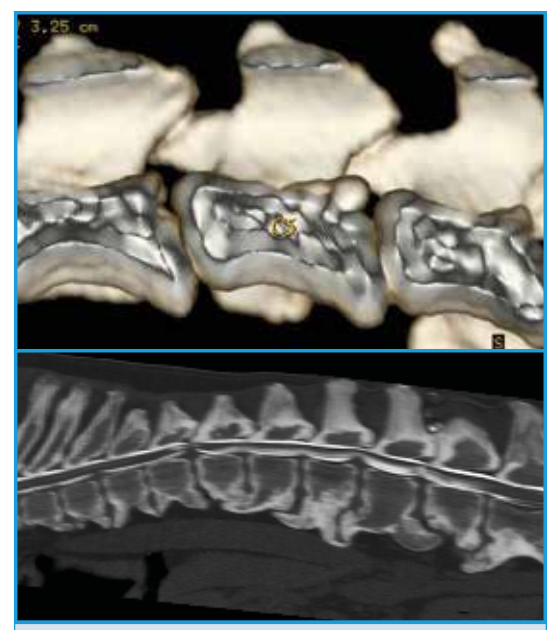

Fig. 12.11 Thoracolumbar disc disease.

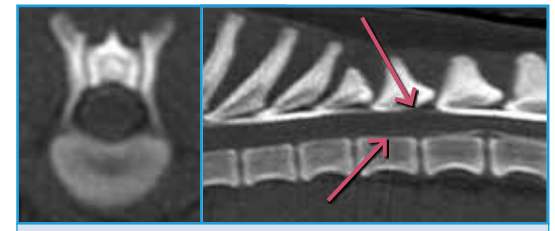

Fig. 12.12 Hansen type III - Reduction of subarachnoid space.

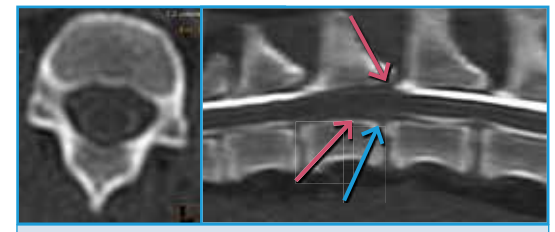

Fig. 12.13 Hansen type III - Reduction of subarachnoid space. *Blue arrow points to the disc herniation (tiny).*

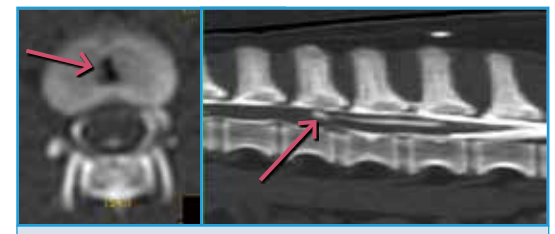

Fig. 12.14 Hansen type III - This is a type III with disc material that has gone through the spinal cord. Described in the ECVN meeting poster (page 290). In the transverse view, gas effect in the disc can be seen, beside the trajectory of disc material.

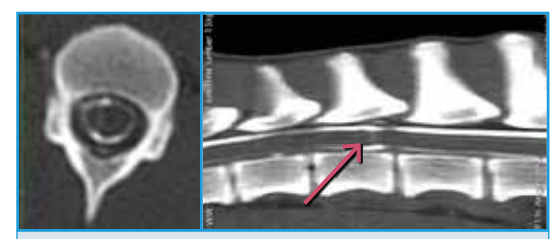

Fig. 12.15 Hansen type III, like fig. 12.14. This is a type III with disc material that has gone through the spinal cord. Described in the ECVN meeting poster (page 290). In the sagittal view, gas effect in the disc can be seen, beside the trajectory of disc material.

Back to the Clinic

A Practical Approach to the Veterinary Neurological and Orthopaedic Patient

Patient assessment is for clinicians, students and specialists a key task in itself. Every aspect of a patient consultation, from the general examination to more specialist orthopaedic or neurological examinations, requires a multidisciplinary approach.

For myself in my clinical work, and before that as a student, with a period as a lecturer in between, I encountered difficulties in patient assessment, as well as in diagnosing and planning practical and effective solutions to the complaints my patients were facing. This was not due to a lack of knowledge or insight, but because practically every subject was presented in a separate book or (now) website. We have separate books for fracture repairs, for neurology, for emergencies and for anatomy and internal medicine.

Now, at the head of a (mostly) referral clinic I felt the need for a practical book bringing together the most relevant subjects. Every small animal veterinary practice sees many neurological and orthopaedic patients, so we clinicians – from students with an interest in these topics to specialists – need an easy reference on anatomy, locomotor assessment and general neurological and orthopaedic examination, as well as rehabilitation, preventive education and advice for owners. This needs to be brought together and arranged in such a way as to provide the clinician grounded advice on whether surgery or a more conservative approach is needed and give direction on what to do and how to do it.

The current manual does all of this, with an important addition: an introduction and special emphasis on the Aharon Method of orthomanual veterinary medicine. The Aharon Method is an animal-friendly, cost-effective approach for treating neurological and orthopaedic patients and for preventive veterinary medicine.

D. C. Aharon, DVM

"A good manual which combines all aspects of locomotor disease diagnosis and management, in a practical manner... for both students and practicing veterinarians."

Z. Polizopoulou, DVM, PhD, Professor, Department of Clinical Studies, Faculty of Veterinary Medicine, Aristotle University of Thessaloniki

"A must-have for every clinician... Follow the described physical examination method and you won't miss a thing on your lame patient."

Birgit Derix, DVM

"An essential guide for those interested in or practicing orthomanual therapy. In addition to comprehensive coverage of this mobilisation technique, the book includes contributions from internationally acclaimed specialists on neurological and orthopaedic examination and interpretation."

Clare Rusbridge BVMS, PhD, DECVN, FRCVS

NVOMD Nederlandse Vereniging voor Orthomanuele Diergeneeskunde

Aharon orthomanuele diergeneeskunde

Flexadin by vetoquinol

Hill's

Ceva

Jacha Heukels DVM, Orthomanual Veterinary Medicine (Aharon Method)

Aharon methode

9 789083 059709

Back to the Clinic

A Multidisciplinary Practical Approach to the Neurological and Orthopaedic Veterinary Patient

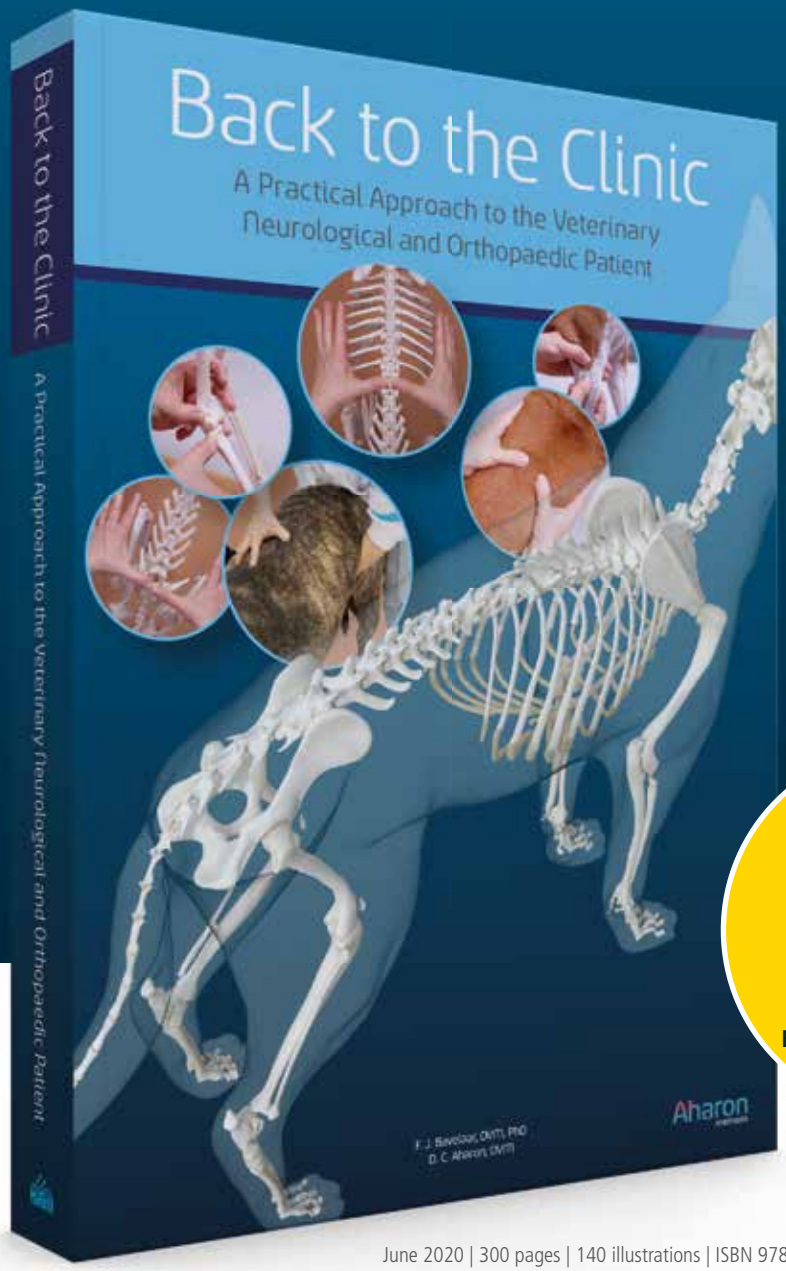

F. J. Bavelaar, DVM, PhD
D. C. Aharon, DVM

With:
Ángel María Hernández Guerra, Prof. DVM, PhD
Franck Forterre, Prof. DVM, DECVS
Laurent Garosi, DVM, DECVN, MRCVS
Paul Mandigers, DVM, PhD, DECVN

ORDER NOW!
€ 99,95
ORDER AT BACKTOTHECLINIC.COM

June 2020 | 300 pages | 140 illustrations | ISBN 9789083059709

This volume is the first-ever handbook on orthomanual therapy for dogs and cats. Written for veterinary surgeons and students of veterinary medicine to guide them in assessing and treating the many neurological and orthopaedic patients they see. Provides a clear and thorough clinical overview of the spectrum of orthopaedic and neurological problems. Helps practitioners identify the best treatment options.

Magis PUBLISHERS

Magis Publishers | info@magispublishers.com | www.magispublishers.com